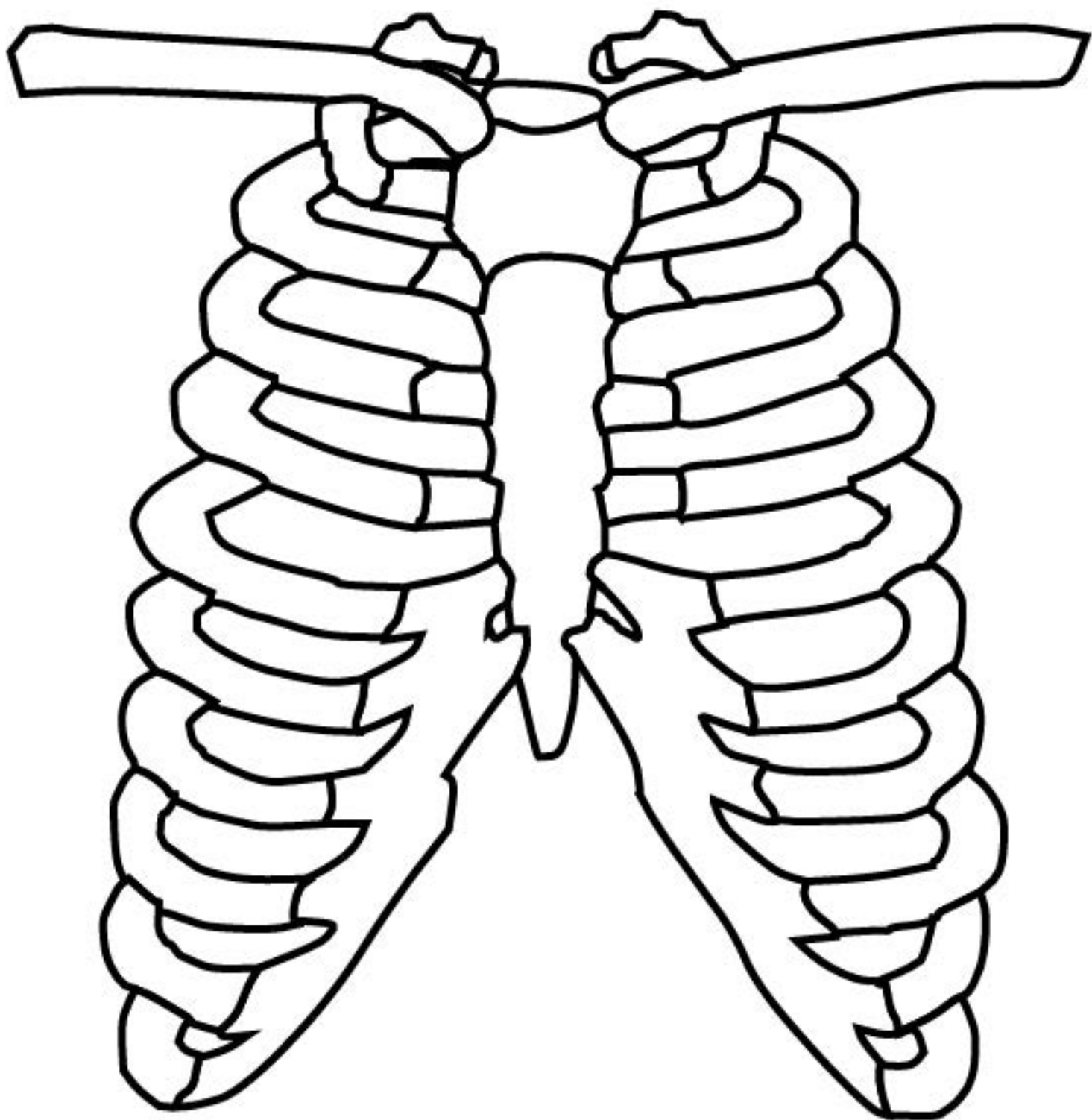
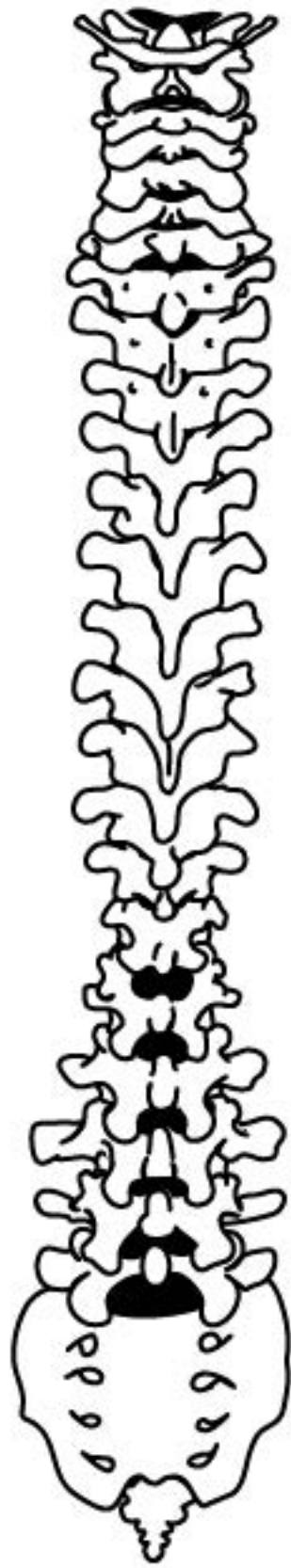

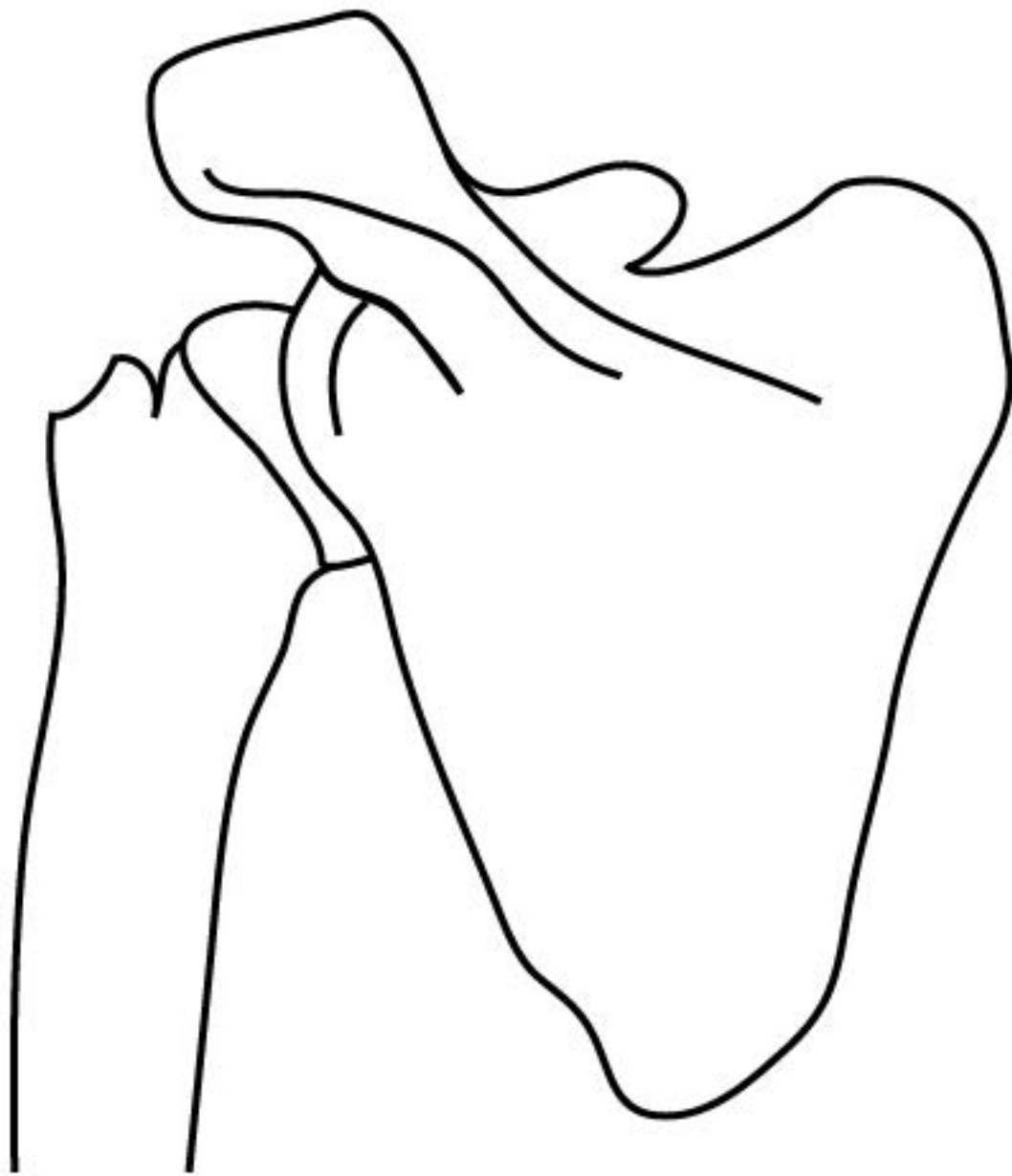SKULL (CRANIUM)



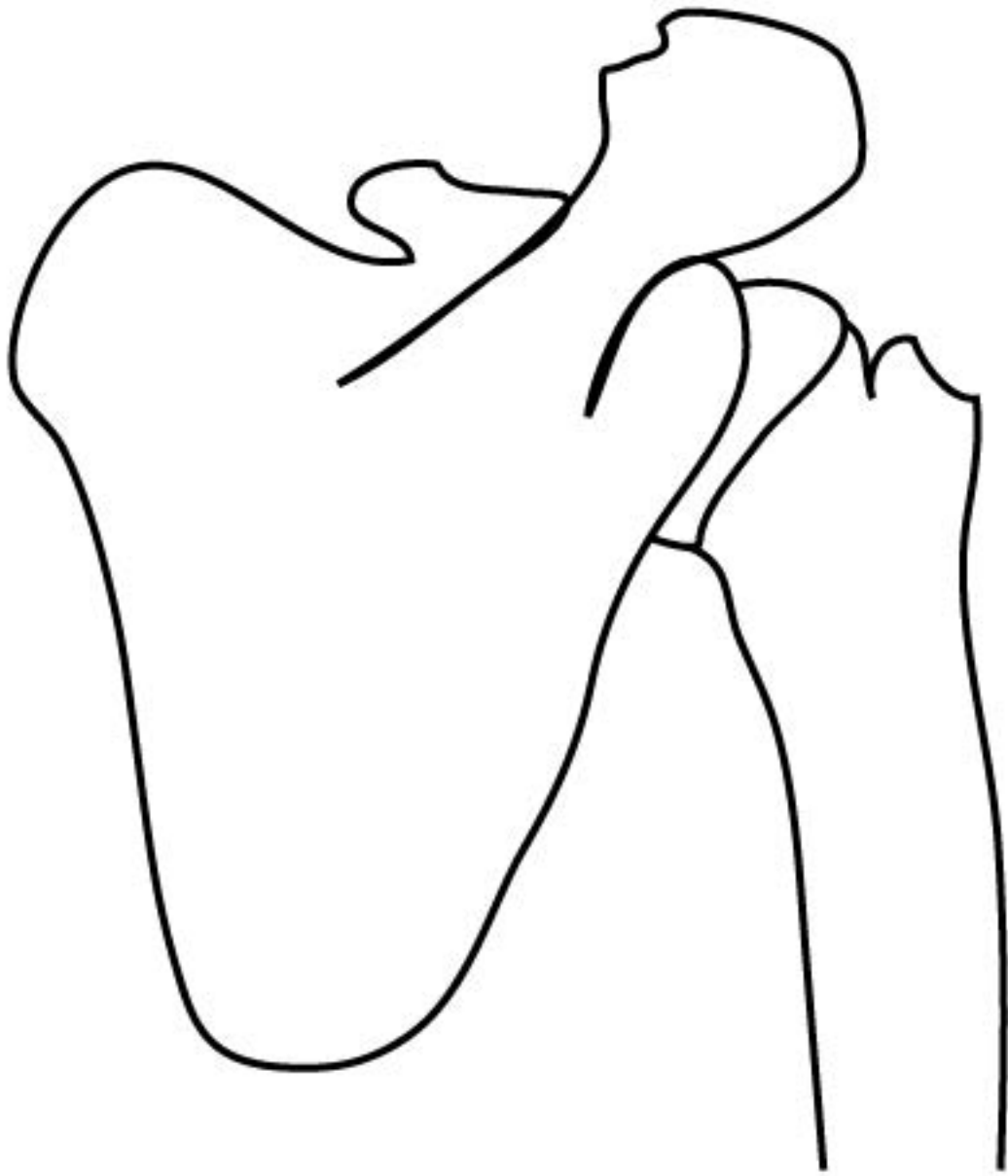
RIBCAGE



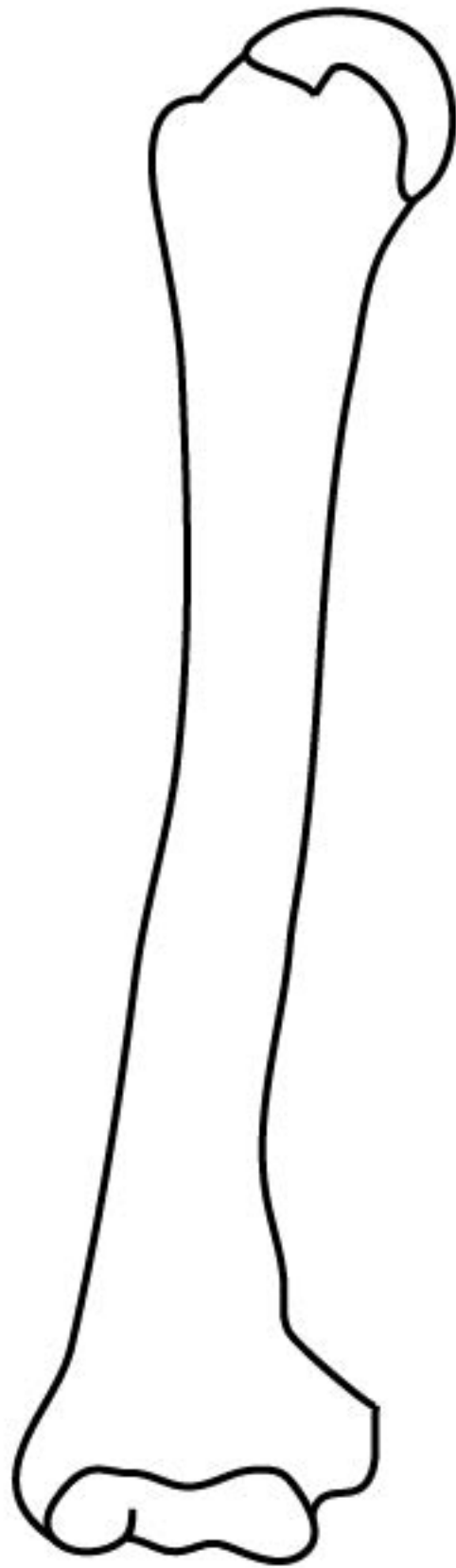
SPINE (VERTEBRAL COLUMN)




LEFT SHOULDER BLADE (SCAPULA)



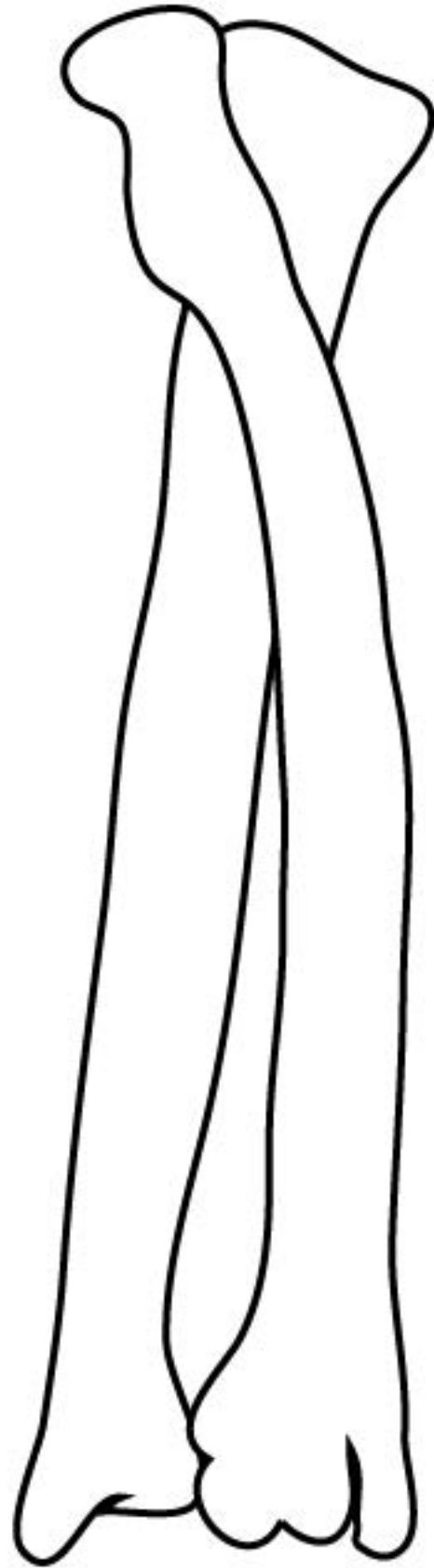
RIGHT SHOULDER BLADE (SCAPULA)



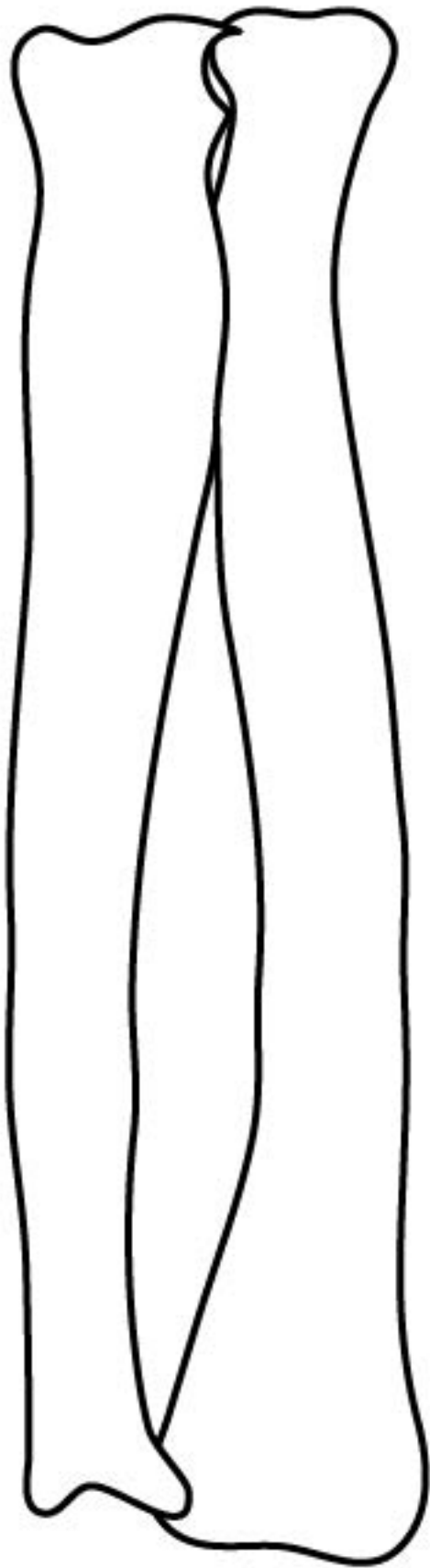
LEFT UPPER ARM (HUMERUS)



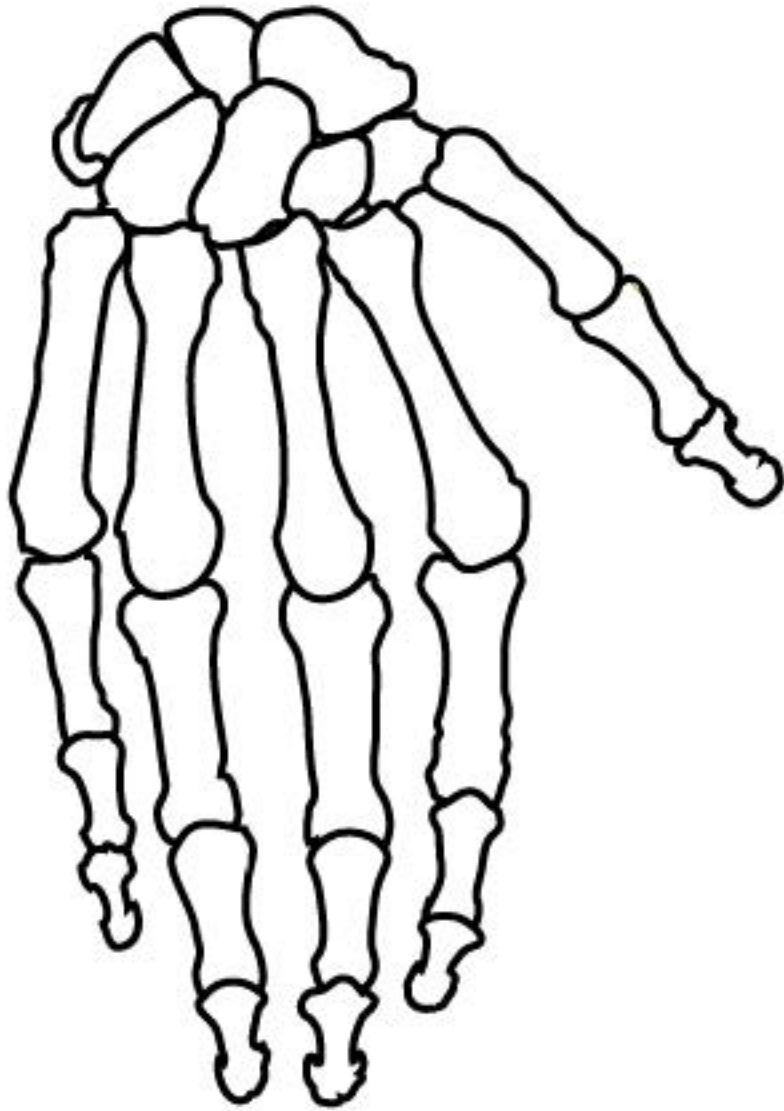
RIGHT UPPER ARM (HUMERUS)



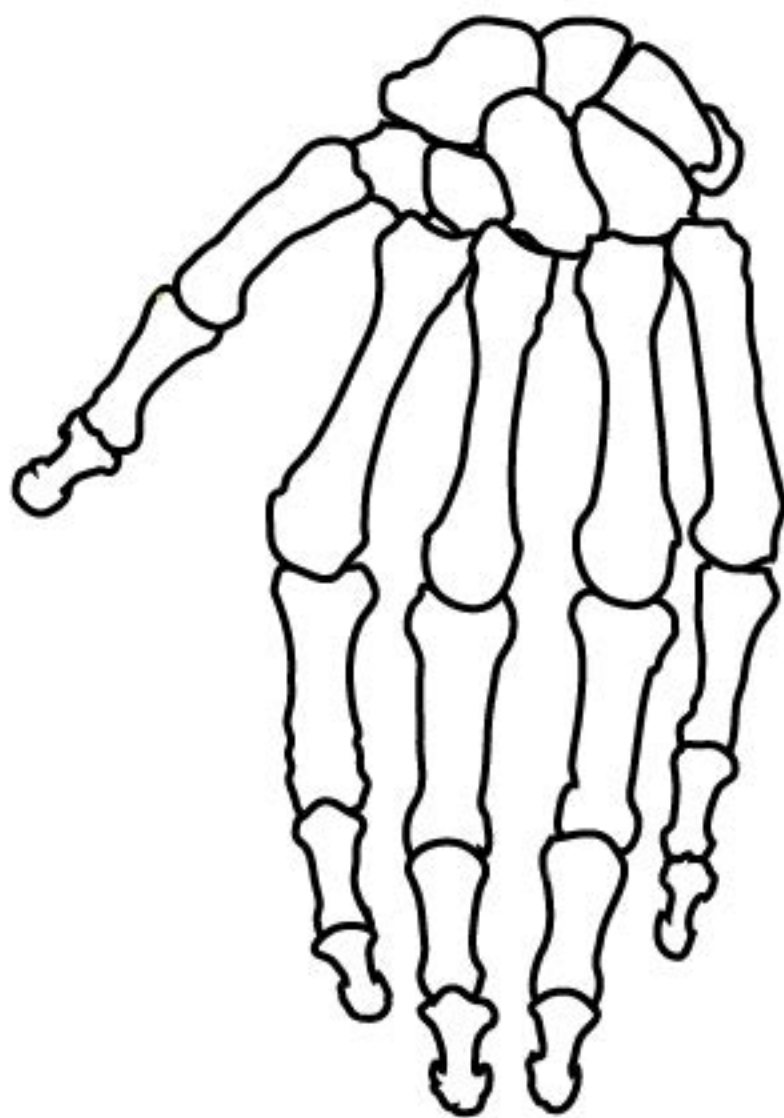
LEFT FOREARM (RADIUS & ULNA)



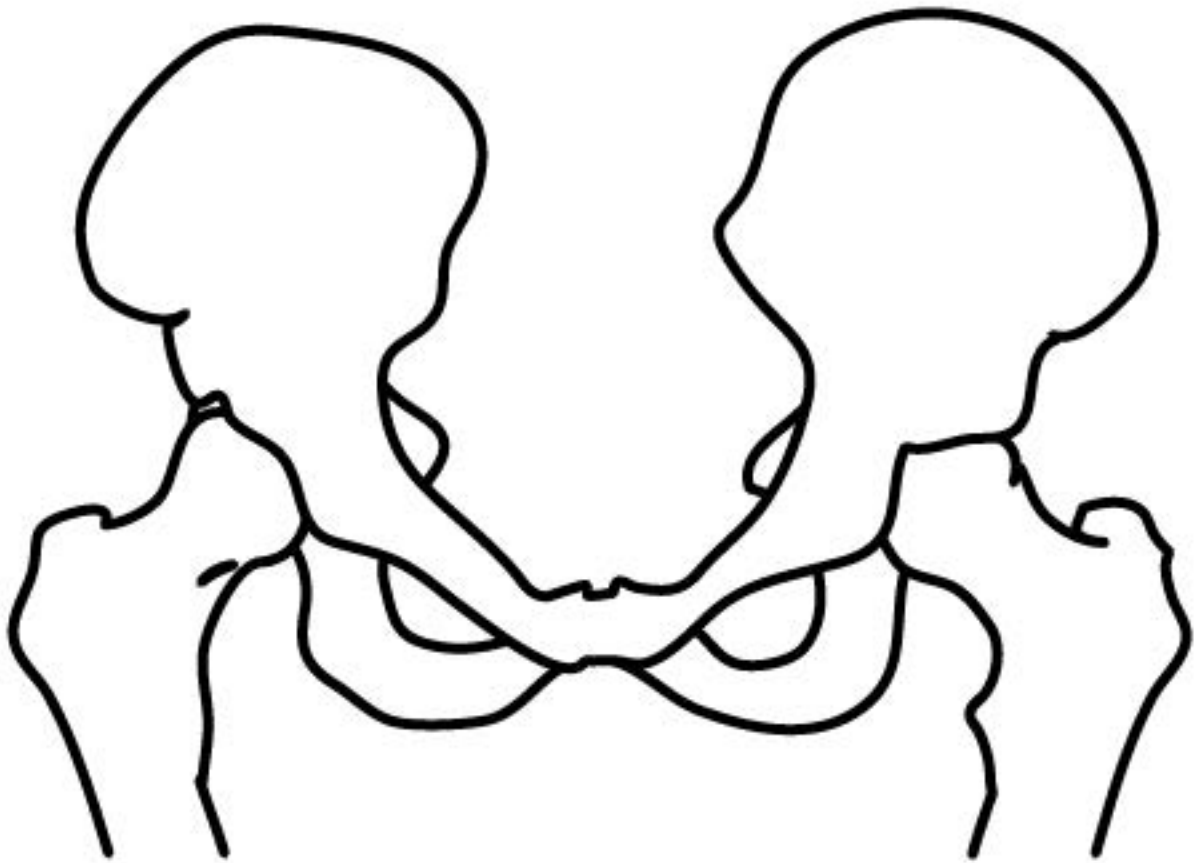
RIGHT FOREARM (RADIUS & ULNA)



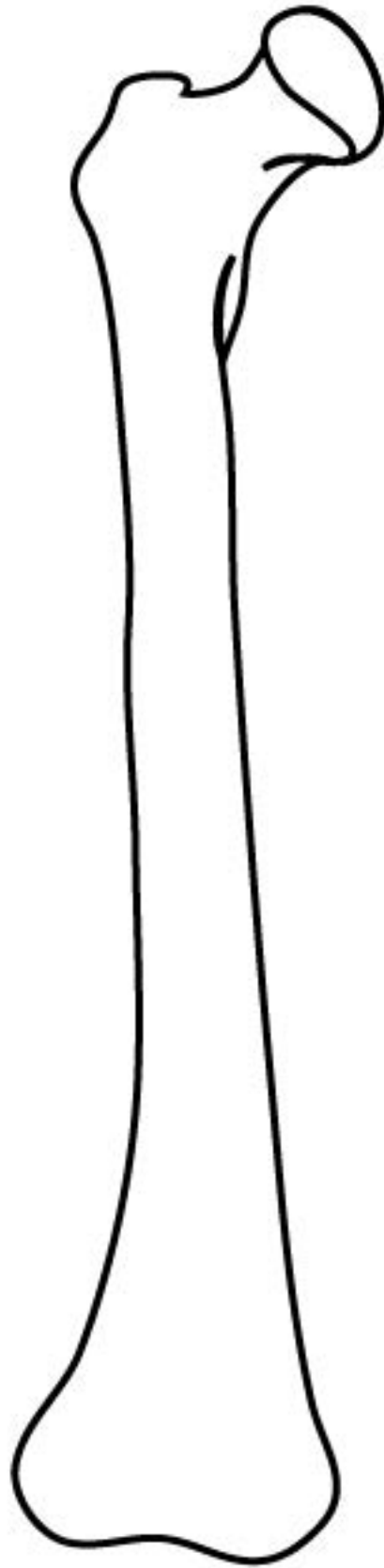
LEFT HAND



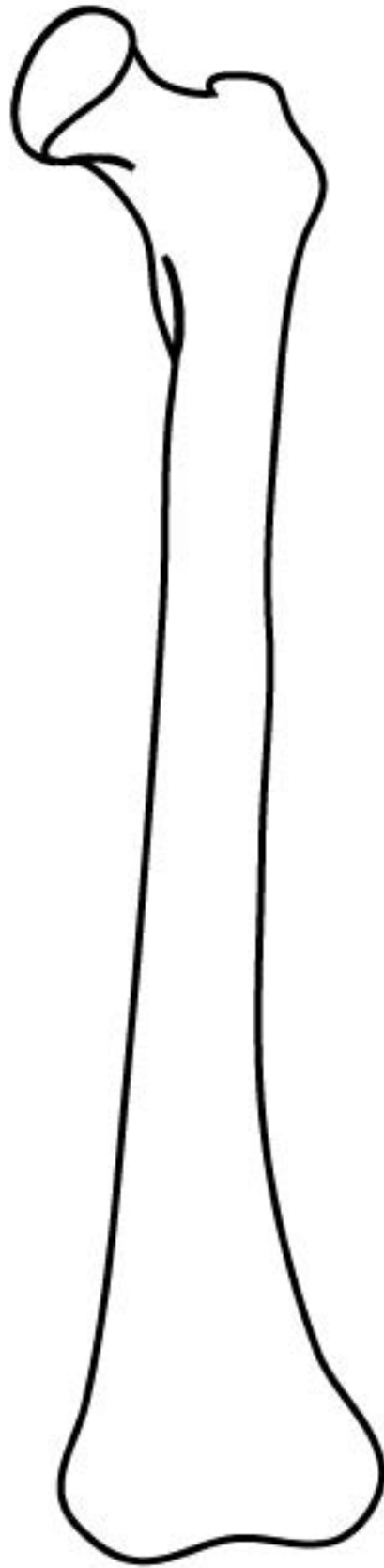
RIGHT HAND



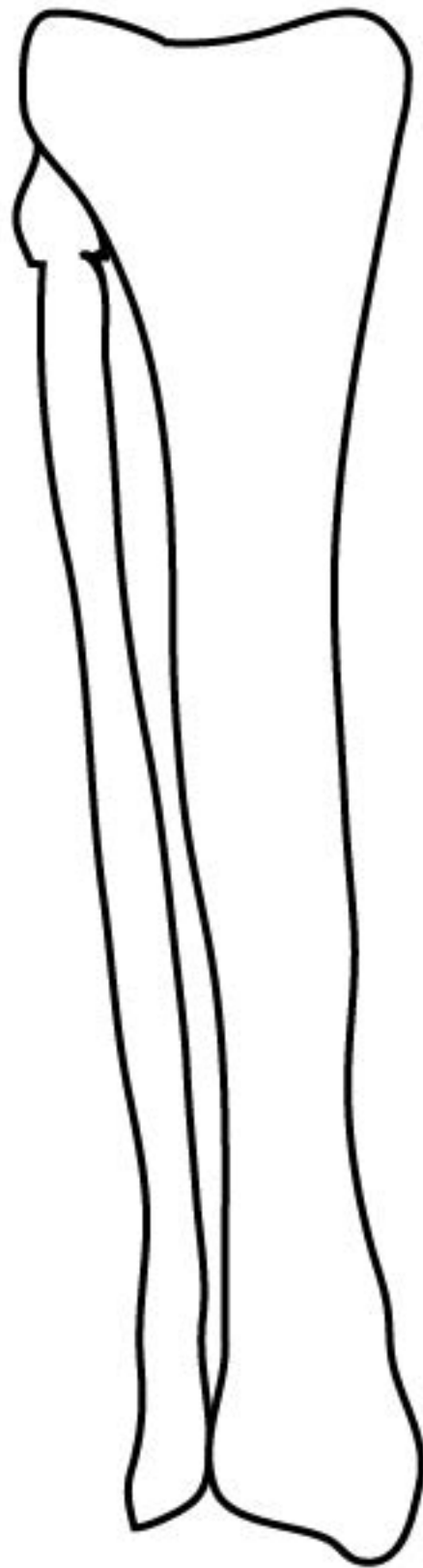
PELVIC BONE



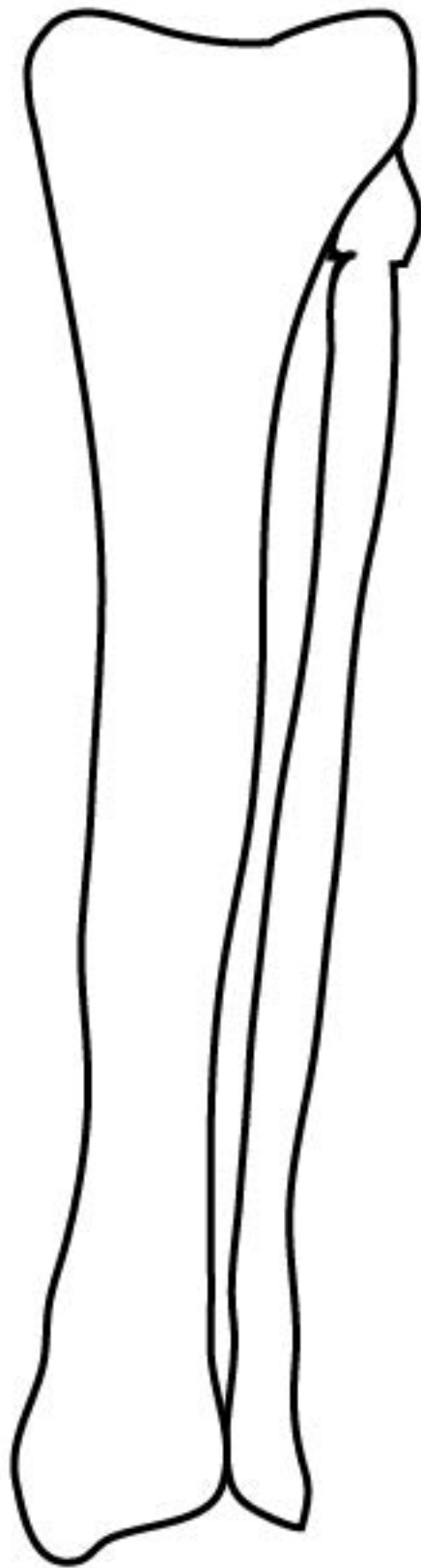
LEFT THIGH (FEMUR)



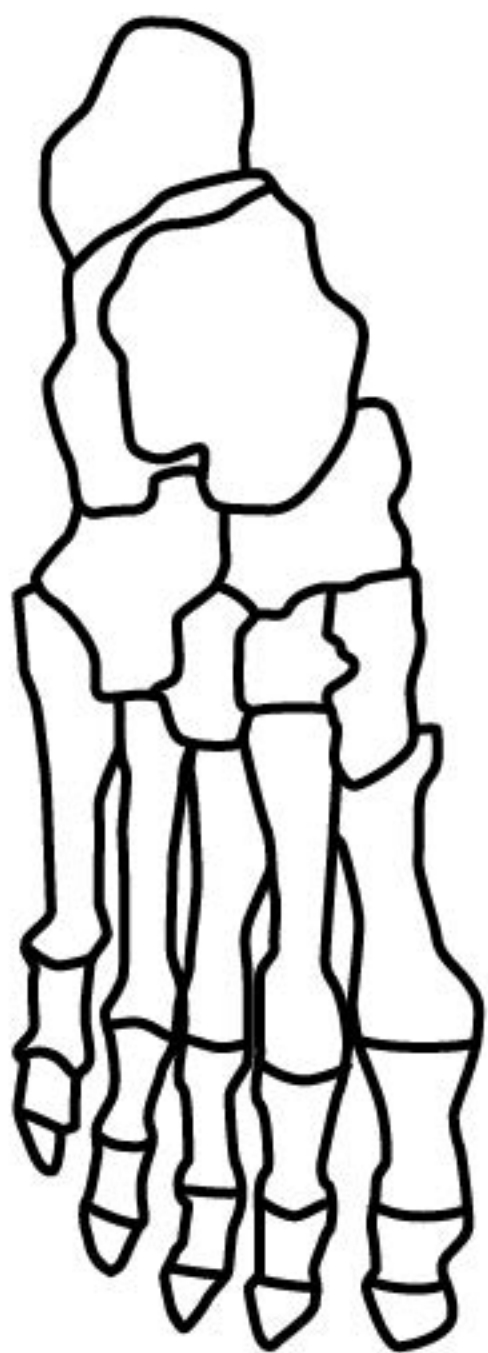
RIGHT THIGH (FEMUR)



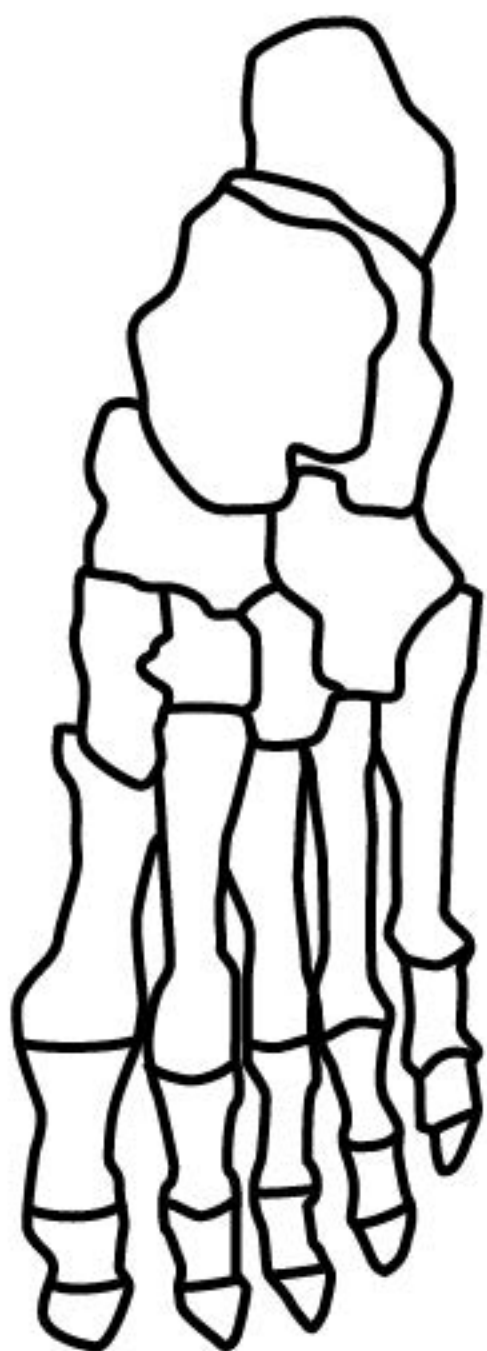
LEFT SHIN (TIBIA & FIBULA)



RIGHT SHIN (TIBIA & FIBULA)



LEFT FOOT



RIGHT FOOT