



iTeachly

Skeletal

Unit 9 Lesson 3

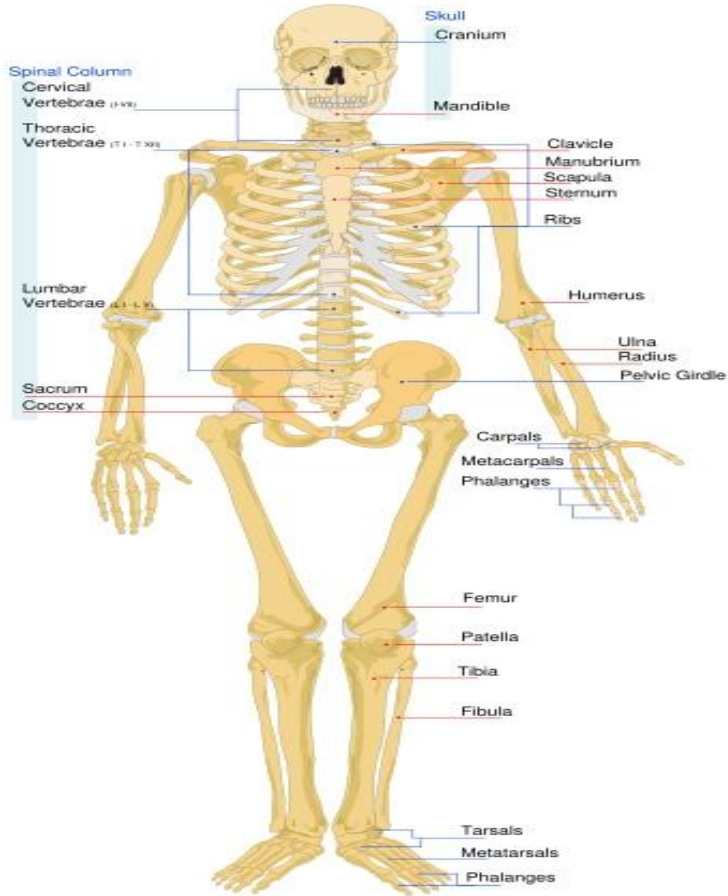
Students will be able to:

- Explain the purpose of the skeletal system.
- Discuss the structure and formation of the bones.
- Distinguish the different types of joints
- Identify the causes of some of the common problems in the bones

Key Vocabulary:

spongy, marrow, ligaments, joints, skeleton

Skeletal



The skeletal system provides form and support to the body. Bones, the major organ

- ✓ protect the vital organs inside the body
- ✓ provide anchor or support to the muscles
- ✓ produce blood cells.

There are two divisions of human skeleton.

- The axial skeleton includes the skull, vertebral column, ribs and sternum.
- The appendicular skeleton includes bones of the arms, hands, legs, feet, shoulders and hips.

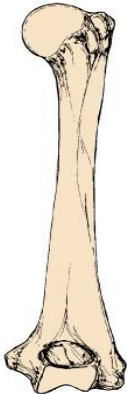
Bone Structure

Bone is a connective tissue. Bones are classified as long, short, flat or irregular.

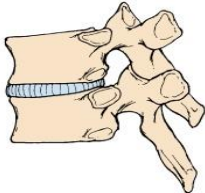
- Arm and leg bones are long bones.
- Wrist bones are short bones.
- The skull is made up of flat bones.
- The bones of the face and vertebrae are irregular bones.

Skeletal

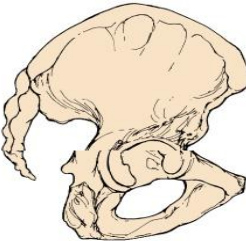
A Long bone: humerus



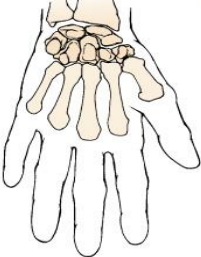
C Irregular bone: vertebra



D Flat bone: ilium



B Short bone: carpals



E Sesamoid bone: patella

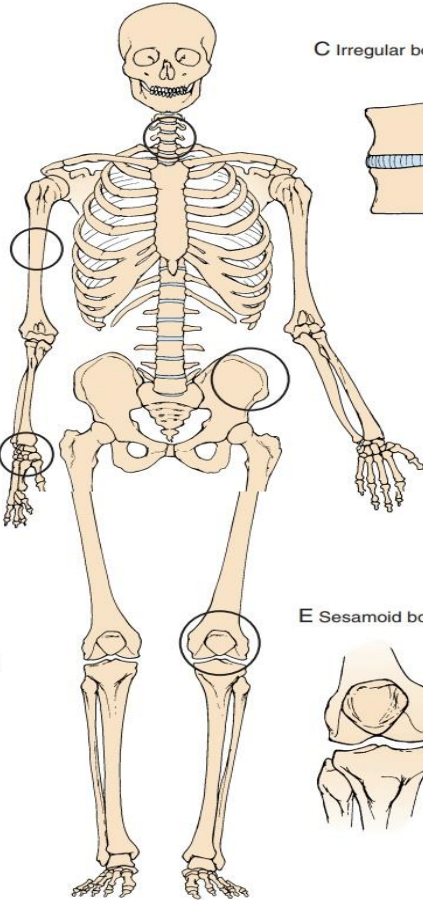
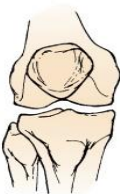

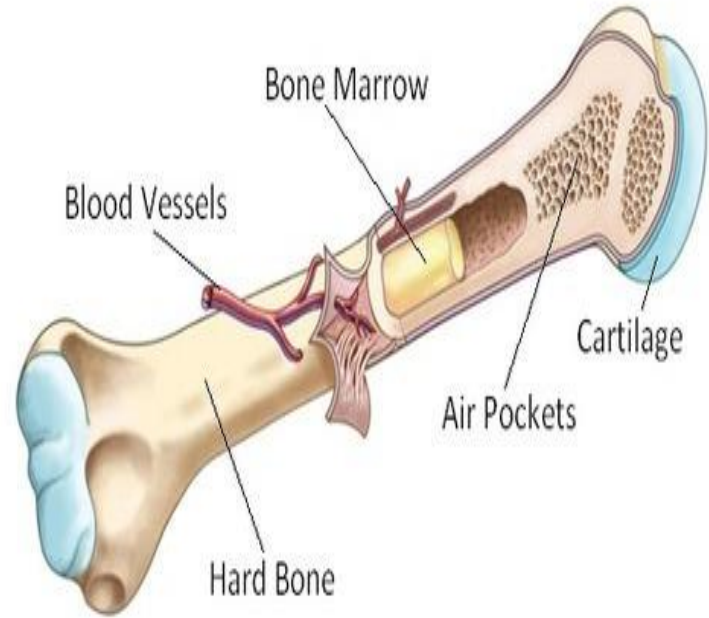
Figure 1: Types of Bones

Skeletal

Bone Marrow

The two types of bone marrow are red and yellow. Red bone marrow produces red and white blood cells and platelets. Red bone marrow is found in humerus, femur, sternum, ribs, vertebrae, and pelvis. Yellow bone marrow in other bones contains stored fat.

Figure 2: Bone Anatomy



Bone formation and repair

The skeletons of embryos are made of cartilage. Bone forms from osteoblasts through ossification. Except for body parts such as nose, ears, and vertebrate disks, the human skeleton is a bone. Osteoblasts are also responsible for bone growth and repair.

Bone are constantly being remodeled, which means old bone cells are replaced with new cells. Cells called osteoclasts break down bone cells, which are replaced with new cells.

Skeletal

When a bone is broken, endorphins flood the area. They reduce the pain for a short time. The injured area swells and a blood clot forms at the break in the bone (see figure 3). New bone begins to form within eight hours. First, cartilage forms at the location of the fracture. This tissue is weak. In about three weeks, osteoblasts form a spongy bone around the fracture. Later, osteoblasts remove the spongy bone while osteoblasts create stronger compact bone to replace it. Splints and casts help keep broken bones in place until new bone forms.

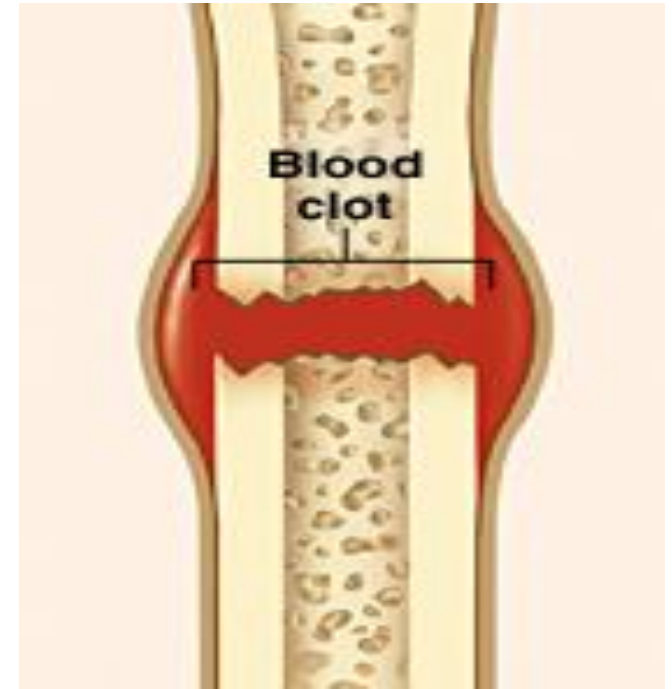


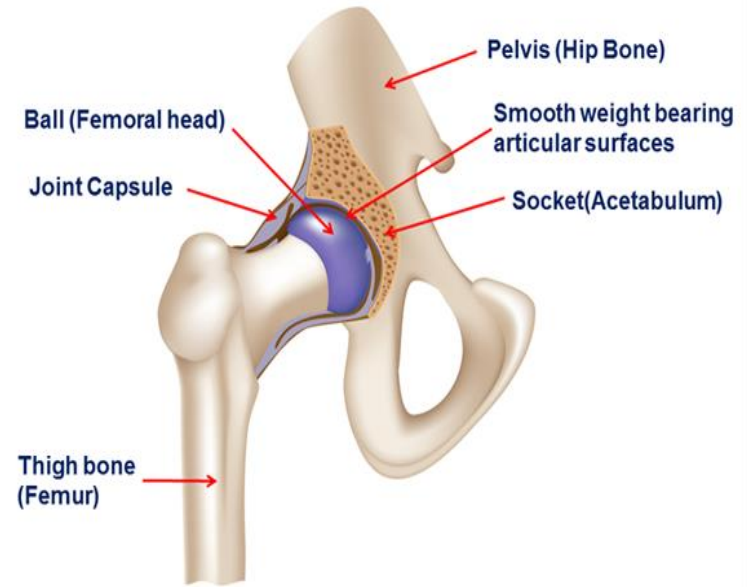
Figure 3: Bone Fracture

Joints

Two or more bones meet at a joint. Each joint allows a certain type of movement except the skull bones. Ligaments hold the bones together. It is a tough band of connective tissue that attach one bone to another.

a. Ball-and-Socket

ball-like surface fits into cuplike depression in another bone; allows widest range of motion, such as swinging arms

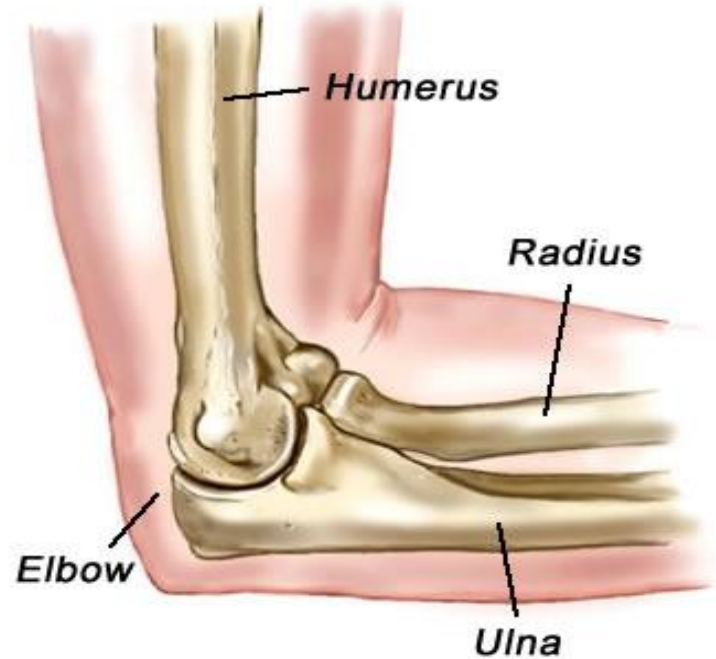

Example: hip joint, shoulder joint

b. pivot

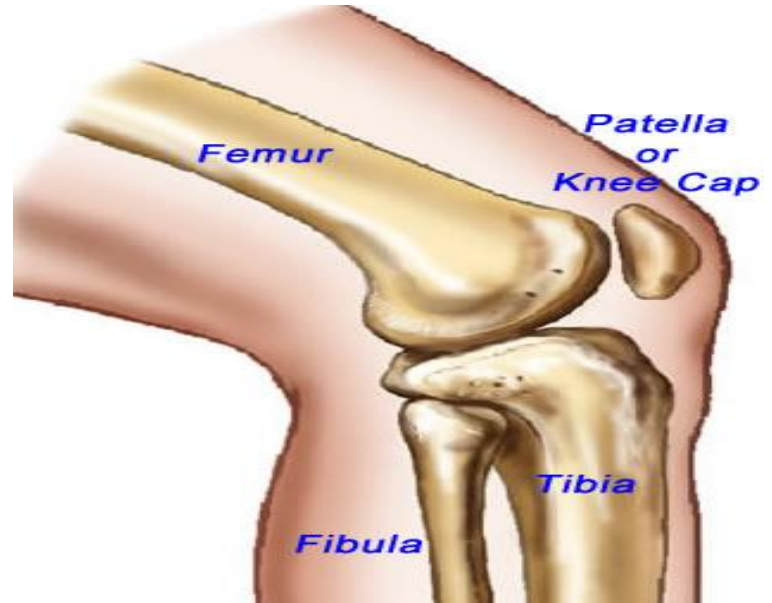
primary movement is rotation, such as twisting lower arm

Example: elbow joint



c. hinge

outward curve of one bone fits into inward curve of another bone; allows back and forth movement

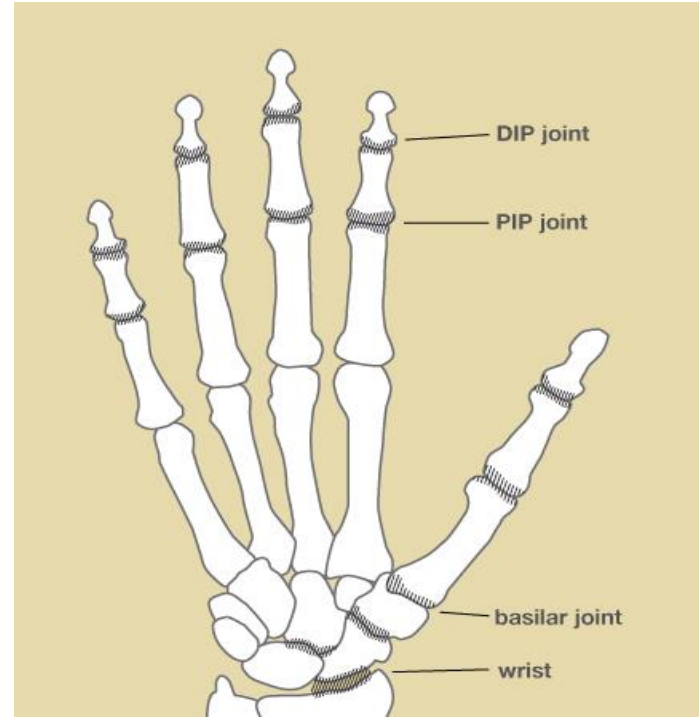


Example: knee joint

d. gliding

allows side to side and
back and forth
movement

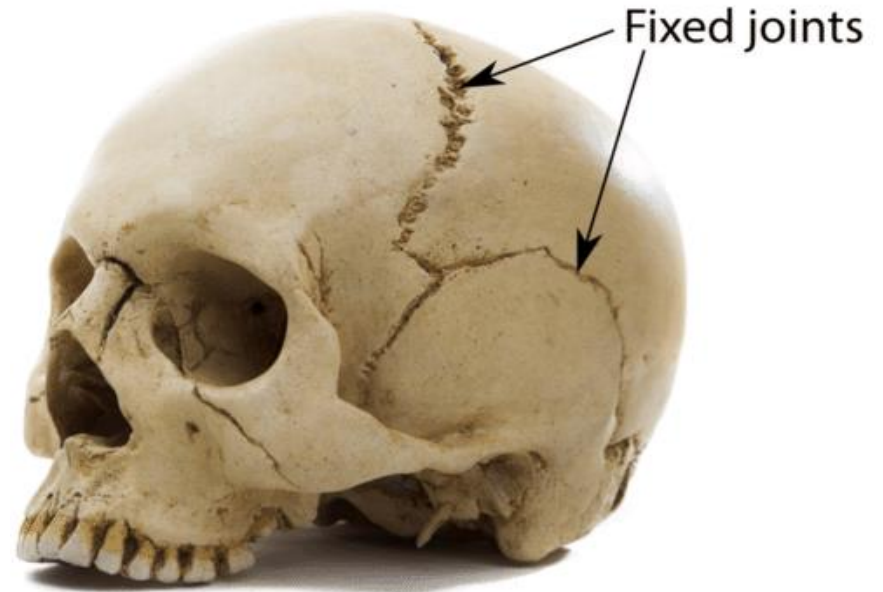
Example: wrist joint, ankle joint
and vertebra



e. sutures

joints in the skull that
are not movable

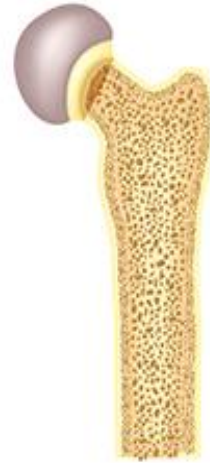Example: skull joint



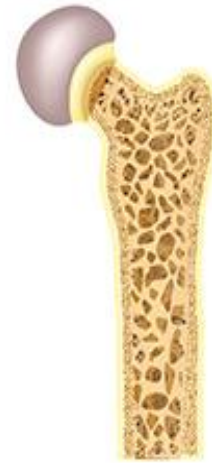Common Problems in the Bones

Osteoporosis

Calcium in the diet is important to bone growth and repair. Too little calcium can lead to a condition called osteoporosis, which results in weak bones that break easily.



NORMAL BONE



BONE WITH
OSTEOPOROSIS

Osteoarthritis is a painful condition that affects joints and results when cartilage in the joints deteriorates. Injury to a joint can result in osteoarthritis.

Rheumatoid arthritis affects the joints but does not result from deteriorating cartilage. Affected joints are swollen and painful. The joints lose both strength and function.

Bursitis is an inflammation of the bursae, causing pain, swelling and reduction in movement.

Sprain is a damage to the ligaments of a joint. Sprains result from overstretching a joint and cause pain and swelling.

Summary

- ✓ **Skeletal system** provides form and support to the body.
- ✓ There are two divisions of human skeleton: **axial and appendicular.**
- ✓ Bones are classified as **long, short, flat or irregular.**
- ✓ The five types of joints are **ball and socket, hinge, pivot, gliding and sutures.**